

A Rare Variant Of An Anterior-Posterior Instability Post Arthroplasty Knee

¹Lee ZC, ²Fairuz S, ²Shahrul H, ¹Satriya S

¹Department Of Orthopedic Surgery, Hospital Selayang

² Faculty Of Medicine Uitm, Sg Buloh

INTRODUCTION:

The posterior stabilized total knee arthroplasty prosthesis is a type of posterior cruciate ligament (PCL) sacrificing implant which PCL is replaced by tibial post and femoral cam preventing posterior tibial subluxation during knee flexion.¹

MATERIALS & METHODS:

A 71-year-old female presented with instability of right knee after 10 years of uncomplicated total knee arthroplasty with a posterior stabilized design prosthesis. Past medical history was unremarkable for any trauma after surgery. On examination, there was evidence of anterior-posterior instability with range of motion of 0-120. Radiographically, prosthetic components remained well positioned without loosening. Blood parameters were negative for infection. Revision surgery encountered a 5x 10mm piece of broken polyethylene which was found to be originated from the post of insert. It was replaced by a new thicker insert size 13mm. During follow up, she showed excellent range of motion with stability in both flexion and extension.

RESULTS:

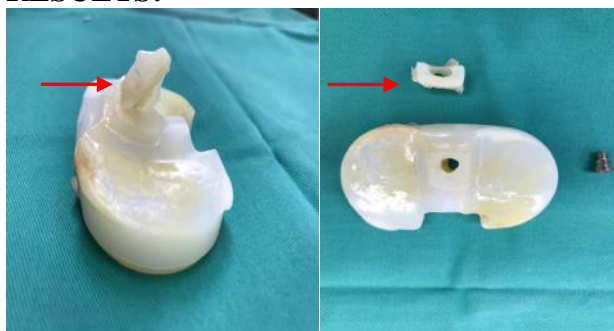


Figure 1

Fig. 1. Pictures showing fracture post of insert. Red arrow indicates level of fracture.

DISCUSSIONS:

Anterior-posterior knee instability secondary to polyethylene tibial post fracture in total knee arthroplasty is reportedly rare, accountable for less than 1% with possible causes of trauma, mechanical stress and in-vivo oxidation.¹ It can manifest as effusion, pain and instability. The peculiarity of our case is it occurred 10 years after operation without history of trauma, we postulated the possible mechanism of anterior-posterior instability is due to heavy mechanical stress with excessive rotation and flexion of femoral component causing asymmetric wear and impingement between the cam and the femoral box resulting in fracture.²

CONCLUSION:

Anterior-posterior instability in total knee arthroplasty should raise the suspicion of polyethylene post fracture.

REFERENCES:

1. Colizza WA et al. Assessment of polyethylene damage and osteolysis after a ten-year minimum follow up. *J Bone Joint Surg Am.* 1995;77:1713.
2. Bozic KJ et al. The epidemiology of revision total knee arthroplasty in the United States. *Clin Orthop Relat Res.* 2010;468:45–51.